

A Study of Vermiform Appendix and Its Various Position in Adults

Syed Nazeer Ahmed¹, Mohammed Khaleel Ahmed²

How to cite this article:

Syed Nazeer Ahmed, Mohammed Khaleel Ahmed. A Study of Vermiform Appendix and Its Various Position in Adults. Indian J Anat. 2020;9(1):69-72.

Author's Affiliation: ¹Associate Professor, Department of Anatomy, Khajabanda Nawaz University, Kalaburagi, Karnataka 585104, India. ²Associate Professor, Department of Anatomy, Shadan Institute of Medical Sciences, Hyderabad, Telangana 500086, India.

Corresponding Author: Mohammed Khaleel Ahmed, Associate Professor, Department of Anatomy, Shadan Institute of Medical Sciences, Hyderabad, Telangana 500086, India.

E-mail: dr.mohammedkhaleel786@gmail.com

Received 09.11.2019 | **Accepted** 02.12.2019

Abstract

Introduction: Aim of our present study was to observe variations of position of vermiform appendix in local population primarily in adults. Totally 50 adult cadavers were dissected during last 5 years for under graduates in the Department of Anatomy, Khaja Banda Nawaz institute of medical sciences, Kalaburagi, Karnataka. Length and breadth, extent of mesoappendix, position of appendix and arterial supply of appendix were studied. In our study most common position was retrocecal, least common was preileal and postileal position. Retrocecal position was seen in 66%, pelvic position was in 26%, subcecal in 4%, preileal 2%, postileal 2% and paracecal position was not observed in any cadaver. In males average length of appendix was 77.20 mm, breadth was 12.42 mm, where as in females length was 69.33 mm, breadth was 10.80 mm. In 34% cases mesoappendix extended up till tip and in 66% cases mesoappendix failed to reach the tip of appendix. In 70% cases single appendicular artery was observed and in 30% cases two appendicular arteries were present. Morphological and positional variations of vermiform appendix is a very important information, to be remembered before planning orduring any surgical procedures to prevent postoperative complications.

Materials and Methods: The present study is of 50 adult vermiform appendix obtained from Department of Anatomy, Khaja Banda Nawaz Institute Medical Sciences, Kalaburagi, Karnataka. The vermiform appendix was observed in cadavers after routine dissection.

Results: In 35 adult male specimens the length

of appendix ranged from 30 mm–120 mm with an average being 77.2 mm. Breadth of the appendix at the base ranged from 7 mm–22 mm with an average being 12.42 mm. Mesoappendix in 17 adults specimens (34%) extended upto the tip and in 33 adults specimens (66%) the mesoappendix failed to reach the tip In 35 (70%), adult cadavers single appendicular artery was observed and in 15 (30%), cadavers double appendicular arteries were observed.

Conclusion: High incidence of retrocecal position and incomplete mesoappendix in our population explains that - diagnosis of acute appendicitis is difficult. A clear cut picture of size, shape and position of appendix is very important to diagnose, based on only clinical presentation of a patient with appendicitis. The area of tenderness in appendicitis will depend upon the position of the appendix, length, part of the appendix with inflammation, direction of the appendix.

Keywords: Retrocecal; Preileal; Postileal; Pelvic; Mesoappendix.

Introduction

As per the universally accepted standard text book, Grey's text book of anatomy, vermiform appendix is worm like tubular, narrowest part of large intestine at structure arising from posteromedial wall of cecum just below the ileocecal junction. Vermiform appendix is present mainly in humans and few arthropod apes. Mesoappendix is a peritoneal fold which suspends the appendix and contains blood

vessels, lymphatics and nerves. Appendix is the only part of large intestine which is devoid of taenia coli, sacculations and appendices epiploicae. Length of vermiform appendix is 2-20 cm, with average being 9 cm. The average diameter at the base is 6 mm. The vermiform appendix is described as having 3 parts: they are base, body and tip. According to Wakeley¹, Sandhyasathyavan² retrocolic and retrocecal position of appendix were seen in 65.28%, 70% of cases respectively. While Delic J³, Ravi Kumar⁴ reported retrocecal position in 38% and 35.8% of and in present study with 26%. This may be due to the increase in length, thickness and function of the appendix due to the presence of extensive mesoappendix.

Materials and Methods

The present study is of 50 adult vermiform appendix obtained from Department of Anatomy, Khaja Banda Nawaz institute of medical sciences, Kalaburagi, Karnataka. The vermiform Appendix was observed in cadavers after routine dissection by the medical student. The length, width, mesoappendix, position of appendix, blood supply of appendix were observed. We observed a few variations which were more regional and such information is essential for all Surgeons. Instruments required are - scale (plastic), divider and other dissection instruments (Fig. 1).

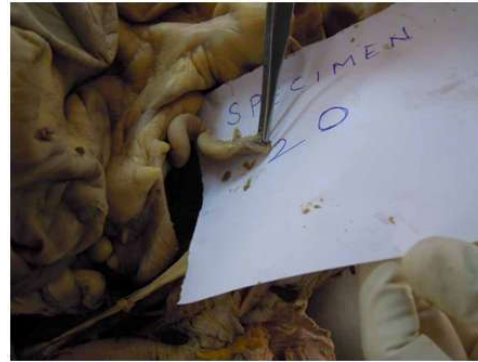


Fig. 1: *In situ*: Vermiform appendix

(LA = Length of appendix, BA = Breadth of appendix)

Results

Length and Breadth of Appendix

In 35 adult male specimens the length of appendix ranged from 30 mm-120 mm with an average being 77.2 mm. breadth of the appendix at the base ranged from 7mm-22 mm with an average being 12.42 mm (Table 1).

Mesoappendix

Mesoappendix in 17 adults specimens (34%) extended up to the tip and in 33 adults specimens (66%) the mesoappendix failed to reach the tip (Table 2).

Table 1: Showing measurements of vermiform appendix in adults

Adult male specimen no	Length in mm	Breadth in mm	Adult female specimen no	Length in mm	Breadth in mm
Total: 35 (70%)	Range: 30 mm-120 mm Average: 77.2 mm	Range: 7 mm-22 mm Average: 12.42 mm	Total No 15 (30%)	Range: 30 mm-100 mm Average: 69.33 mm	Range: 5 mm-20 mm Average: 10.8 mm

Table 2: Showing mesoappendix in adults

Adult specimen No.	Meso appendix extends up to tip	Meso appendix failed to reach the tip
Total No 50	17 (34%)	33 (66%)

Table 3: Showing positions of vermiform appendix

Adult specimens	Preileal	Postileal	Pelvic	Retro Cecal	Sub Cecal	Para Cecal
50	1	1	13	33	2	Nil
Percentage	2	2	26	66	4	Nil

Table 4: Showing arterial supply of appendix

No of cadavers	One appendicular artery	Double appendicular artery
50	35	15
Percentage	70%	30%

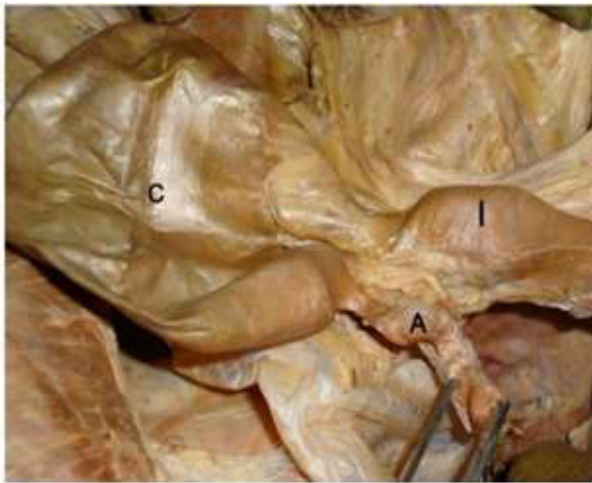


Fig. 2: Vermiform appendix in preileal position

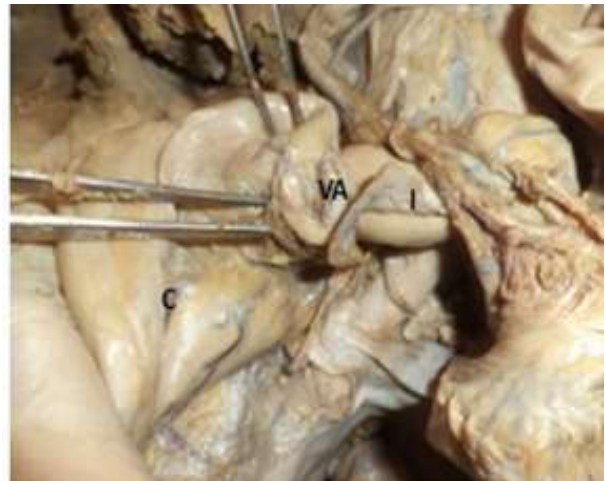


Fig. 5: Vermiform appendix in retrocecal position

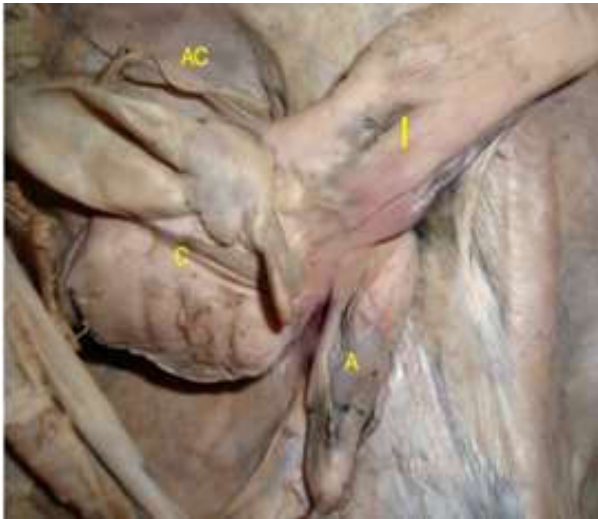

Fig. 3: Vermiform appendix in postileal position

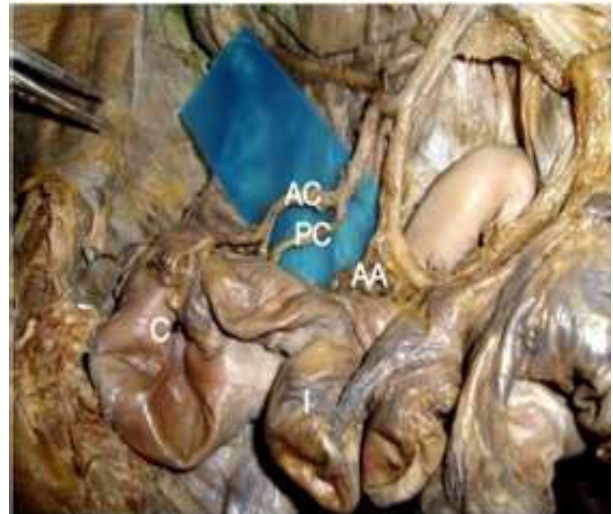

Fig. 6: Showing single appendicular artery

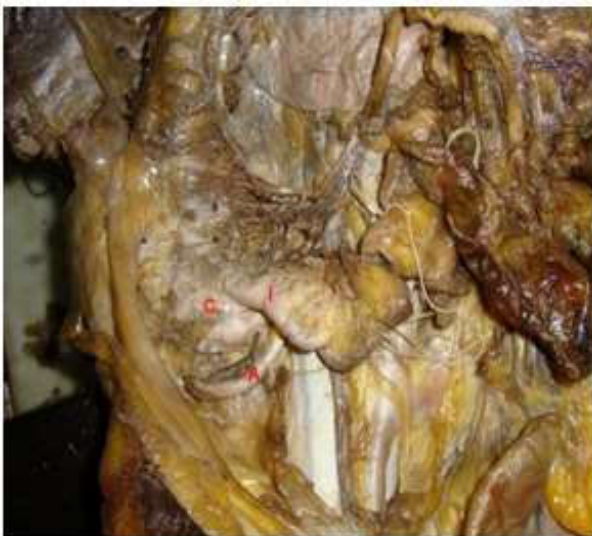

Fig. 4: Vermiform appendix in subcecal position

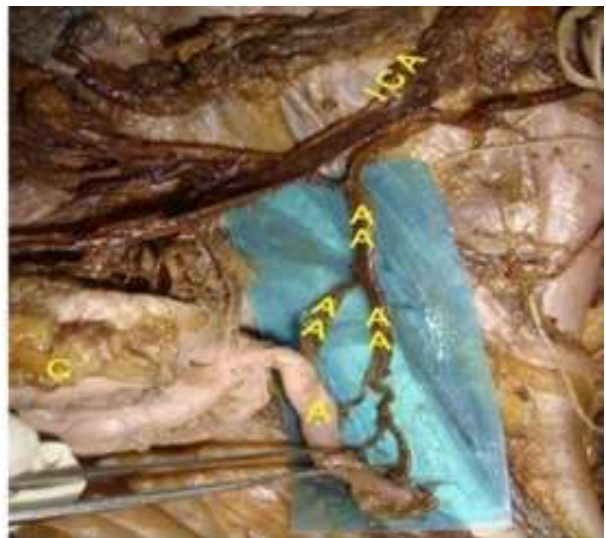

Fig. 7: Showing double appendicular artery

Discussion

In our present study, retrocecal position was observed in 66% of cases respectively. Retrocecal position was the common in our study and least common position was preileal and postileal position. Paracecal position was not observed in any case. The percentage of pelvic position seems to be high in north Karnataka. In our study, the length of the appendix was longer in Males than Females. Length of appendix in adult males was 9.2 cm and in adult females was 9.12 cm but average length was 7.72 cm.⁵ Breadth of the appendix was 5 mm and 6.7 mm respectively. But in present study, breadth was in the range of 6–12 mm. The increased thickness of appendix in our local population may be related to their dietary habits.^{6,7} Observed one appendicular artery in 39.8% & 39% of cases respectively. In our present study, one appendicular artery was present in 70% of cases and 2 arteries were observed in 30% of cases.⁸⁻¹⁰ As per Datta AK, described the positions as subcecal, paracolic, retrocecal, retrocolic, splenic, promonteric, pelvic and miclinguinal.¹¹

The meso appendix is a triangular peritoneal fold, enclosing the appendicular artery and appendix. This extends to a variable length. As per AK Datta¹¹ and Keith L More.¹³ The mesoappendix is extending upto the tip of the appendix, whereas, as per Hollinshead¹² and Last the mesoappendix extends to a variable length.

Conclusion

The relations, measurements, positions and arterial supply are studied by gross dissection in 50 specimens (50 adults) from the population of North Karnataka, Kalaburagi.

- It is observed that the relations of the appendix are same in all specimens, irrespective of adults.
- In adult males the length of the appendix varied from 4.5 cms to 5.5 cms and in the females from 4.5 cms to 6 cms. 4.5 cms to 5.5 cms and in the females from 4.5 cms to 6 cms longer than in males in adults.
- Retrocecal positions are more common, being 52% in adults.
- The extent of the mesoappendix is variable and in the present study both complete and incomplete types are observed.
- In all the specimens, the lumen of appendix is not obliterated.

- High incidence of Retrocecal position and incomplete mesoappendix in our population explains that diagnosis of acute appendicitis is difficult.

References

1. Wakely CPC (Grays). The position of vermiform appendix as ascertained by an analysis of 10000 cases. *J Anat.* 1933 Jan;67(Pt 2):277–83.
2. Sandhya sathyavan, Maheshwari S, Bala Subramanyam. et al. Study of position of the appendix in abdominal operations. *Anatomical Adjuncts* 1995 Sep;2(1):78.
3. Delic J, Savokovic A, Isakovic E. Variations in the positions and point of origin of the vermiform appendix. *Med Arh* 2002;56(1):5–8.
4. Ravikumar U, Bapuji P, Ratnaprabha Ch, et al. Human vermiform appendix. The position and extent of mesentery, arterial supply studied in 134 adult cadavers. *J Anat Soc India* 2009;58(1):47–111.
5. Raja Ram V. Position of appendix in 50 cadavers and postmortem bodies. *Anat Adjuncts* 2005 sep;4(2)Abstract 24.
6. Wood Jones F. *Buchanansmanules of anatomy* Woodjones F, 8th edition. London: BallizarTendail Co; 1948.pp.756–59.
7. Varma PK, Alam K. The morphological and histological variations in the appendix from human to herbivores and carnivores mammals. *J Anat Soci, India* 2007;56(1):55–108.
8. Katzarski MM, Gopalrao UK, Brandy K. Blood supply and position of vermiform appendix in Zambians. *Med J Zambia* 1979 April–May;13(2):32–34.
9. Ajmani ML, Ajmani K. The position, length and arterial supply of appendix. *Anat Anz.* 1983;153(4):369–74.
10. Scheye Th, Dechelotte P, Tanguy A, et al. J Anatomical and histological study of ileocecal valve. *Journal Surgical and Radiological Anatomy* 1983 June;5(2):83–92.
11. Datta AK. *Essentials of Human Anatomy*, 3rd edition, Calcutta: Current Books International 1996.pp.226–28.
12. Hollinshead HW. *Anatomy for surgeons vol II, Thorax, Abdomen and Pelvis*, 2nd edition. New York: Medical Department Harper and Row Publishers; London: Evanston, San Francisco; 1971.pp.484–86, 493–510.
13. Keith L Moore. *Clinical oriented anatomy*, 3rd edition. 203–205. London: Williams and Wilkins; 1992.pp.203–5.